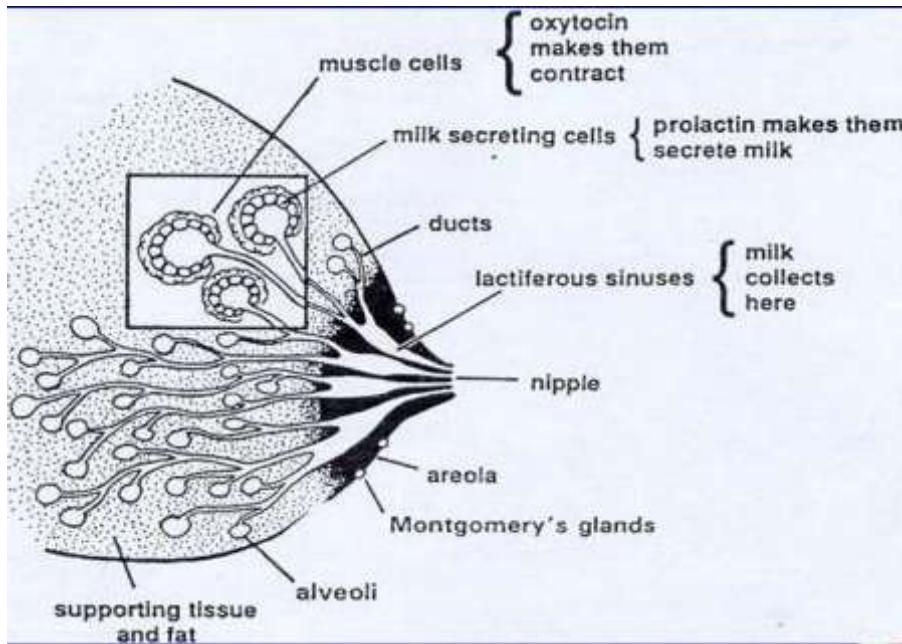


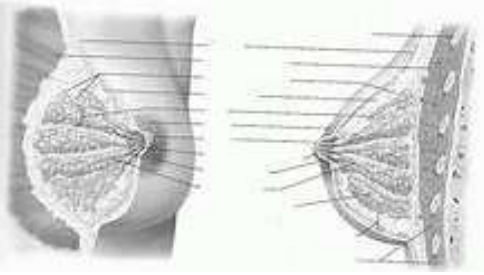


**X. Relevant Normal Features
Breast**

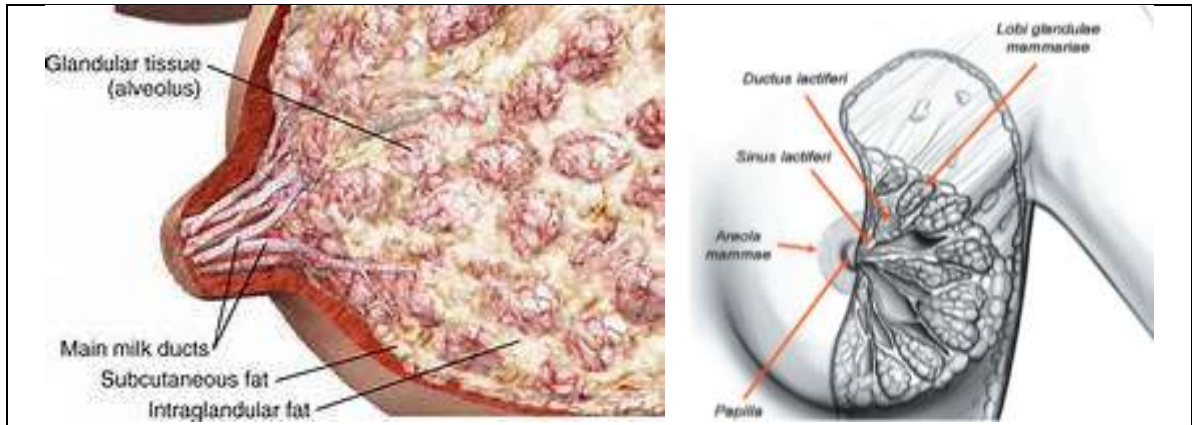


BREAST		<i>On each side of anterior chest wall</i>	
	<i>Each comprises:</i>	<ol style="list-style-type: none"> 1. Mammary gland 2. Superficial fascia 3. Skin; Including: Nipple & Areola 	
<i>In Male</i>	<i>1. Nipple:</i>	<i>Small Pointed</i>	
	<i>2. Areola:</i>	<i>Surrounded by sparse hair</i>	
	<i>3. Mammary gland:</i>	<i>Rudimentary</i>	
<i>In Female</i>	<i>1. Nipple:</i>	<ul style="list-style-type: none"> • <i>Eminence below mid-point</i> • <i>Cylindrical (base)</i> • <i>Conical</i> • <i>Brownish-pink</i> • <i>Wrinkled</i> • <i>Have secondary papillae</i> 	

		<ul style="list-style-type: none"> • <i>Have 15-20 orifices</i> • <i>Encircled by areola</i> <p><i>No fat</i></p>
	2. Areola:	<p><i>A circular patch of coloured skin</i></p> <p><i>Rosy pink</i></p>
	In virgin:	<i>Delicate</i>
	In pregnancy:	<ul style="list-style-type: none"> • <i>Dark brown</i> • <i>Pigmented</i> • <i>Enlarged</i> • <i>Shows sebaceous glands: Large during lactation.</i>
	3. Mammary gland:	<p><i>Before puberty: Small</i></p> <p><i>At puberty: Enlarged</i></p> <p><i>During pregnancy: More enlarged</i></p> <p><i>At lactation: Much enlarged</i></p> <p><i>At old age: Atrophied</i></p>
		

General characters

<ul style="list-style-type: none"> • <i>A wide-based conical mass</i> • <i>Smooth</i> • <i>Rounded</i> • <i>No capsule</i> • <i>Not enclosed in a fascial sheath</i> • <i>Fat in hollows between projections</i> 		
Stroma:	<i>Compactly-arranged</i>	
Glandular tissue :	<ul style="list-style-type: none"> • <i>Pale-reddish</i> • <i>Lobes, lobules, ducts and sinus</i> • <i>Opens on summit of nipple</i> • <i>Firm</i> 	



Deep surface :	<ul style="list-style-type: none"> • <i>Flattened</i> • <i>Slightly concave</i> • <i>Irregular</i> • <i>Circular (more or less)</i> 		
Subcutaneous surface:	<i>Convex</i> <i>Presents: Nipple & Areola</i>		
<i>Other features</i>			
<i>An extension of breast tissue → axillary appendage</i>			
<i>Stroma of breast:</i>			
<i>Dense collagenous connective tissue heavily admixed with fat → yielding consistence</i>			
<i>Breast of a virgin:</i>	<i>Epithelial component may not be apparent by the naked eye but it may constitute about 15% of the breast-bulk.</i>		