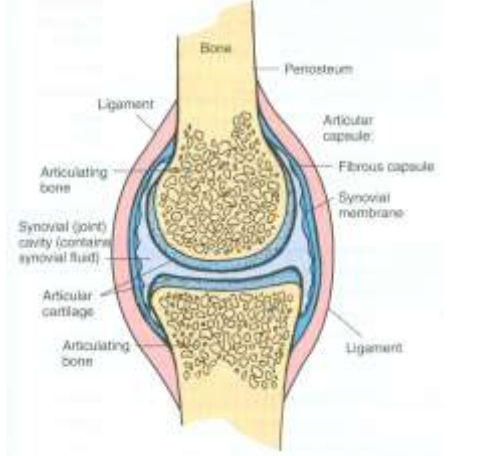
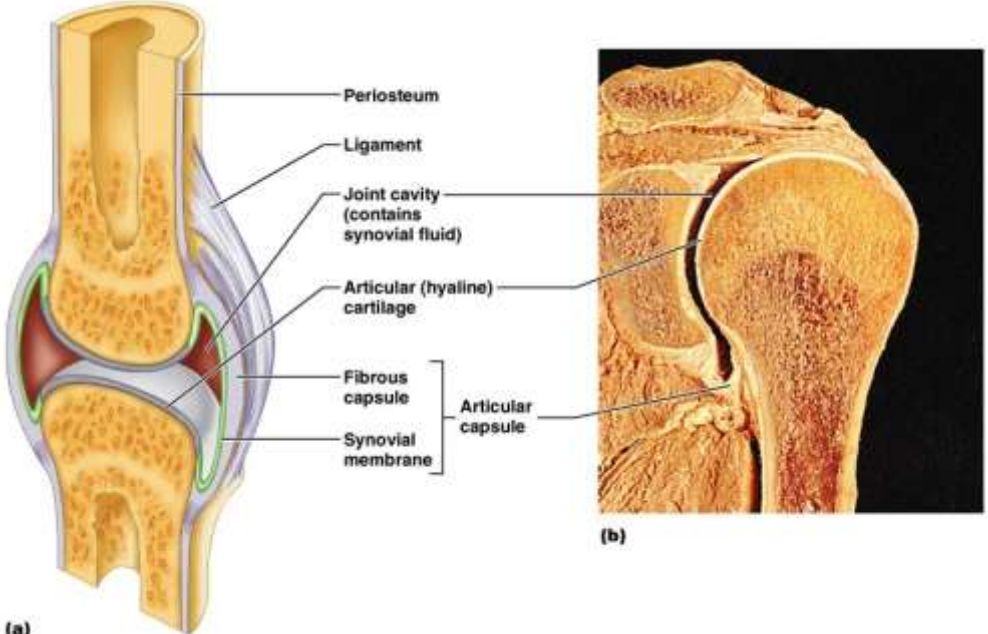


**X. Relevant Normal Features**  
**Joints and scalp**

<b>JOINTS</b>				
<b>As an example:</b>	<b>A synovial joint:</b>	<b>1. Bones are united by a joint-capsule</b>		
		<b>2. The joint-cavity contains synovia</b>		
		<b>3. A hyaline articular cartilage</b> <b>Forms: A smooth coating to the opposing bones</b>		
		<b>4. Two layers form the capsule:</b>		
		<b>1. Capsular ligament:</b>	<ul style="list-style-type: none"> <li>• <b>Outer</b></li> <li>• <b>Short</b></li> <li>• <b>Wide</b></li> <li>• <b>Of fibrous tissue</b></li> </ul>	
	<b>2. Synovial membrane:</b>	<ul style="list-style-type: none"> <li>• <b>Inner</b></li> <li>• <b>Velvety</b></li> <li>• <b>Very vascular</b></li> </ul>		
				
<p><b>(a)</b> Copyright © 2004 Pearson Education, Inc., publishing as Benjamin Cummings.</p>				

<b>SCALP</b>	<i>The soft structures covering the skull</i>	
	<i>From eyebrows to superior nuchal lines between temporal lines</i>	
	<i>Soft</i>	
	<b>Arranged in layers:</b>	
	<i>Skin</i>	
	<b>Fascia:</b>	<i>Firm Fibro-fatty Adherent to skin</i>
	<ul style="list-style-type: none"> <li>• <i>Aponeurosis (epicranial)</i></li> <li>• <i>Loose areolar tissue</i></li> <li>• <i>Periosteum (pericranium)</i></li> <li>• <i>Muscles in temporal regions</i></li> </ul>	

