

XV. Diseases of the Cardiovascular System

Fallot's Tetralogy			
Heart	Is enlarged Shows patent interventricular septum (high) Displacement of the aorta to the right side Pulmonary stenosis		
Right ventricle	Is hypertrophied		
Left ventricle	Appears relatively-small in size		

Tetralogy of Fallot

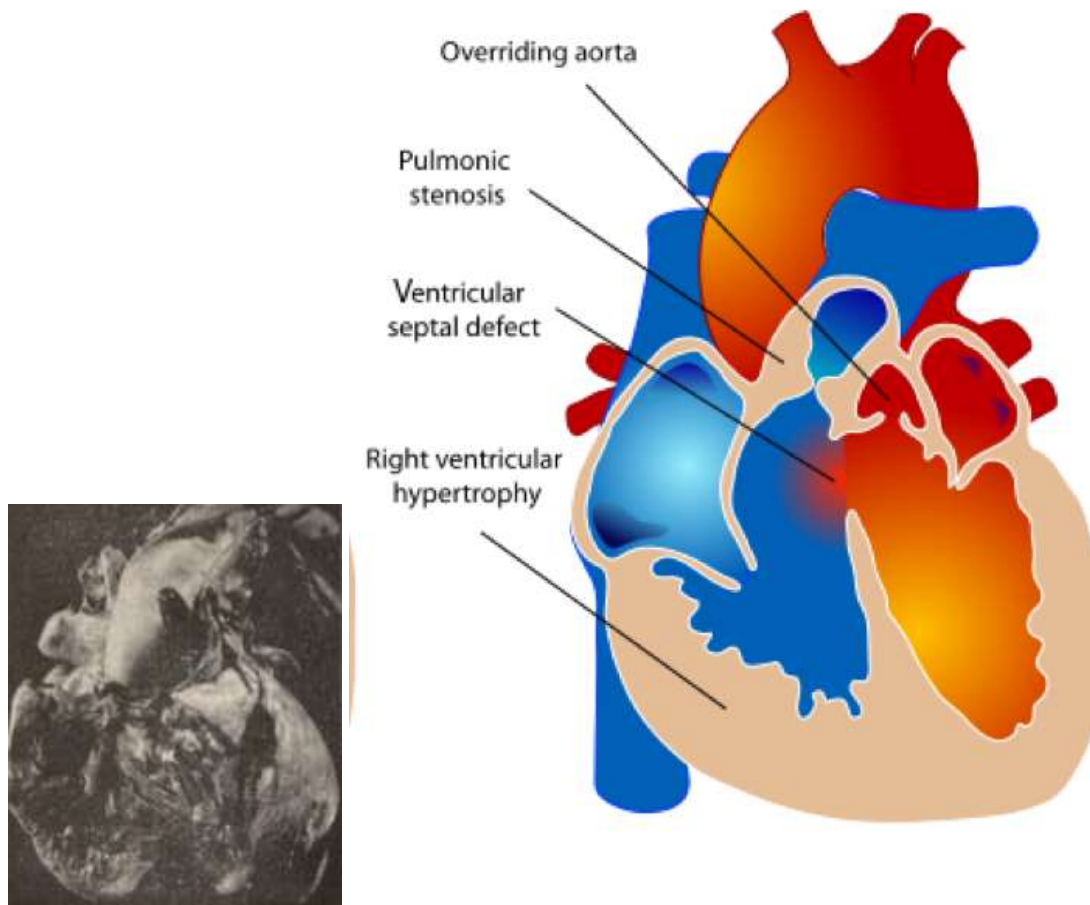
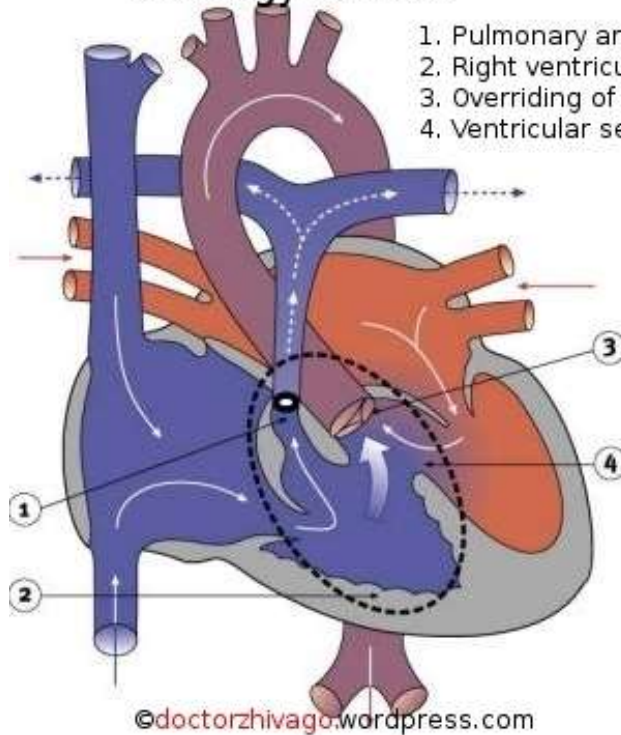


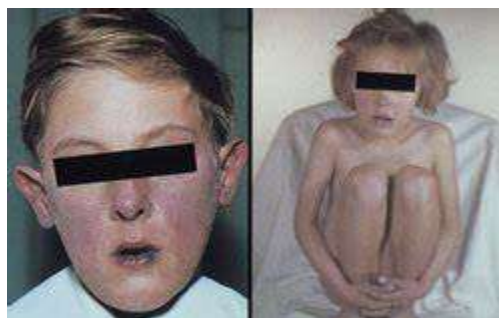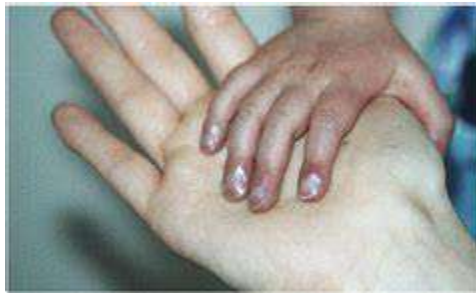Figure 43
Nature Fallot's Tetralogy
Specimen No. 1-2.822
Reference P. 127

Tetralogy of Fallot



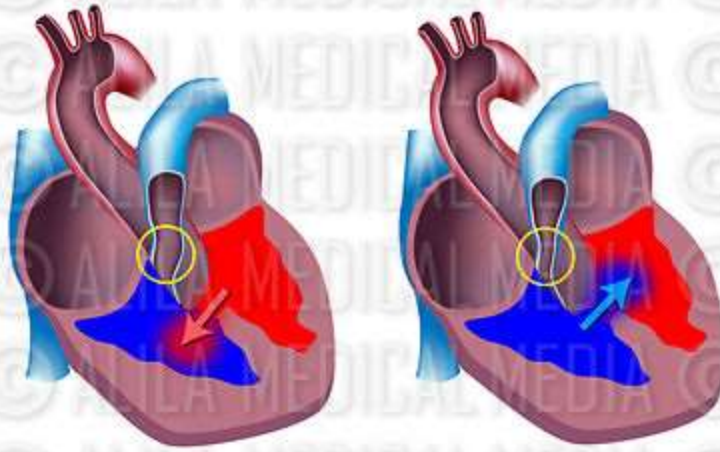
Heart Defects with Decreased Pulmonary Blood Flow

- Pulmonary Stenosis
- TOF-Tetralogy of Fallot



MILD Pulmonary Obstruction

SEVERE Pulmonary Obstruction



© Alila Medical Media - www.AlilaMedicalMedia.com