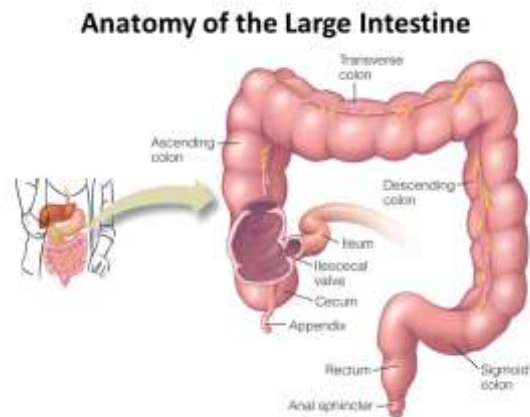
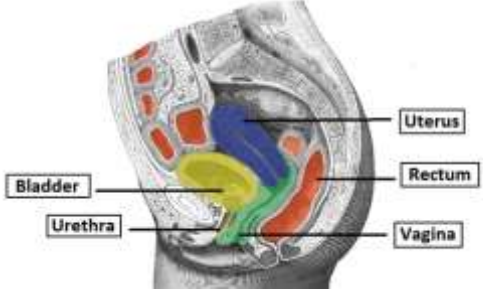
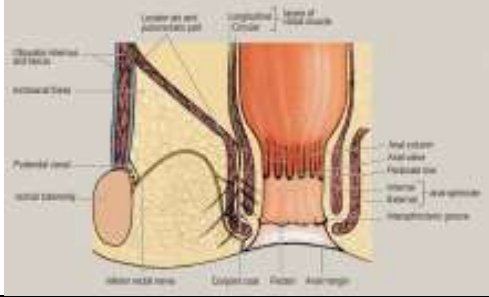


Rectum and anal canal



(c) RECTUM AND ANAL CANAL		
(a) RECTUM		
	<i>Just above anal canal</i>	
Begins at:	<i>End of pelvic colon</i>	
Ends at:	<i>Anal canal</i>	
Length:	<i>12 cm</i>	
<i>Curved anteroposteriorly</i>		
Flexures:	<i>3 sideway bends</i>	
Lower 1/3	<i>Devoid of peritoneum</i>	
	<i>Embedded in loose fascia</i>	

<i>Separated from bladder by</i>		<i>Seminal vesicles Vas deferens</i>	
<i>Directly related to</i>		<i>Sheath of prostate</i>	
<i>In female Relation is to</i>		<i>Uterus Vagina</i>	
<i>Mucosa</i>	<i>Thick</i>		
	<i>Raised into</i>	<i>3 horizontal folds</i>	
<i>Ampulla of rectum</i>		<i>Lowest part Distended</i>	

(6) ANAL CANAL		Terminal portion of large intestine	
<i>Begins at :</i>	End of rectum		
<i>Ends at :</i>	Anus		
<i>Length :</i>	2-3 cm.		
Mucosa			
• <i>At upper 1/2</i>	<i>Longitudinal ridges (anal columns)</i>		
	<i>Lower ends of anal columns :</i>	<i>Connected by semilunar folds (anal valves)</i>	
	<i>Anal valves :</i>	<i>At junction of mucous and cutaneous parts</i>	
• <i>At lower 1/2</i>	<i>Lined with skin</i>		

c) ANUS

Lower aperture of alimentary canal
(anal orifice)

Skin :

**Folded
Hair**

Develops in skin at puberty
(in males)

