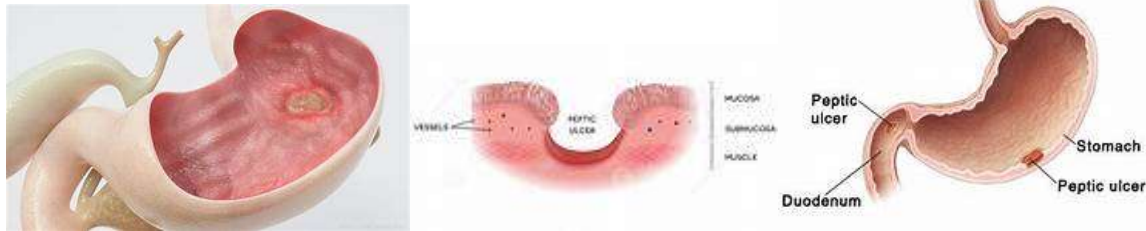


XVII. Diseases of the Digestive System

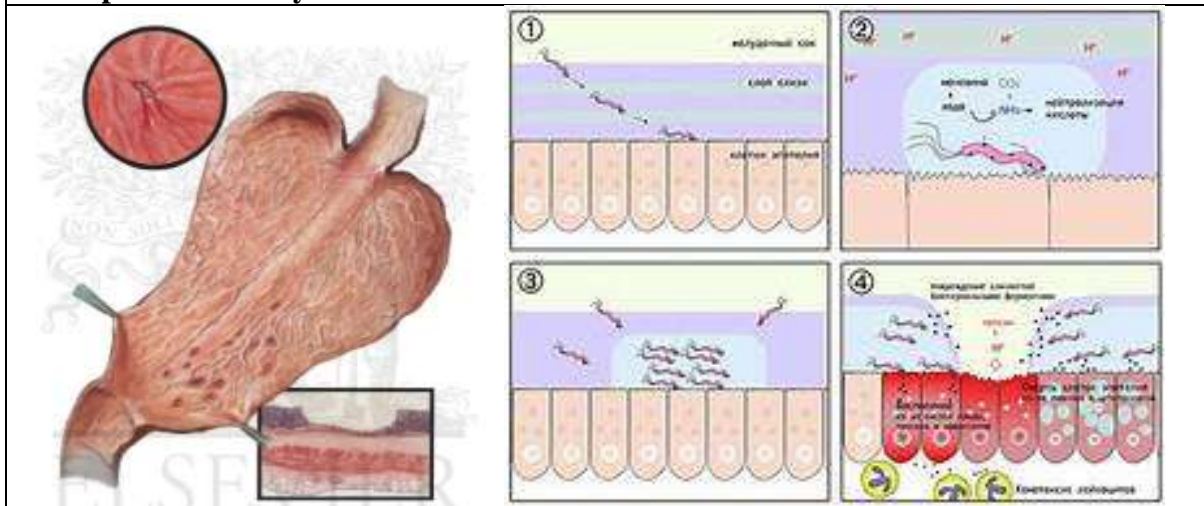
Peptic Ulcer (acute) III - 3.1851

Stomach:	Shows ulcers and evidences of gastritis	
Ulcers:	<ul style="list-style-type: none"> • Are scattered in the mucosa • Three ulcers are definitely apparent • Are small in size (0.5 to 1 cm.) • Two are superficial and surrounded with slight inflammatory reaction (haemorrhagic erosions) • One ulcer is rather deep and has penetrated to the submucosa 	
Outline:	<ul style="list-style-type: none"> • Irregular in parts; sharp in parts 	
Edges:	<ul style="list-style-type: none"> • Steep (or somewhat undermined or poorly-defined) 	
Floor:	<ul style="list-style-type: none"> • Clean in one ulcer; • Covered with dark brown necrotic material in the other ulcers 	
Base:	<ul style="list-style-type: none"> • Thick oedematous submucosa or muscularis mucosa. • No induration 	




N.B.:


- This stomach shows two very shallow and superficial ulcers (erosions) and one acute ulcer.
- **Peptic ulcers may be acute or chronic.**




COMMON CAUSES THAT LEAD TO PEPTIC ULCERS




HELICOBACTER PYLORI BACTERIAL INFECTION




NONSTEROIDAL ANTI-INFLAMMATORY DRUGS




ZOLLINGER-ELLISON SYNDROME




ALCOHOLIC BEVERAGES



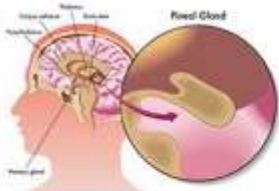
EXCESS STRESS




HYPERCALCEMIA




FAMILY HISTORY



LOW LEVELS OF MELATONIN





To explore more, visit www.Top10HomeRemedies.com

Causes of peptic ulcer SS

- Stress
- Smoking
- Spirits
- Steroid & Non-steroidal anti-inflammatory drugs
- Salicylates
- Sepsis
- Scolding food
- Spices
- Strong tea and coffee
- Some others like
 - Zollinger Ellison syndrome
 - Family history
 - Helicobacter pylori associated gastritis

