

XVII. Diseases of the Digestive System

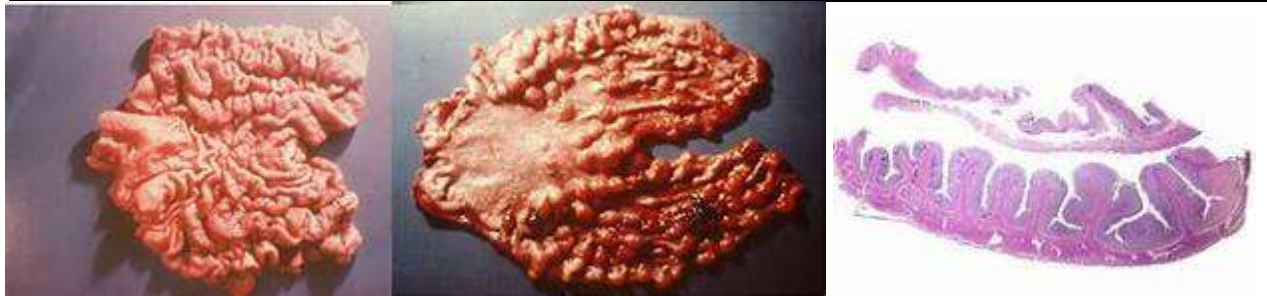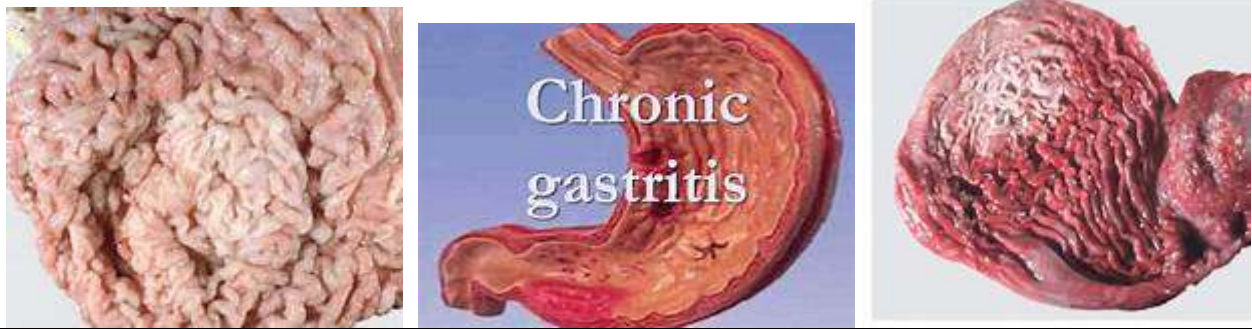
Chronic Gastritis (hypertrophic) III - 3.321

Stomach	Is thickened throughout its mucosa	
	Wall :	Hypertrophied and velvety
	Mucosa:	Coarse folds Mammillated appearance

N.B.:

It used to be called "hypertrophic type" of gastritis.

- Occasionally, few small polypoidal formations occur and the condition has to be differentiated from a type of carcinoma called "**linitis plastica**".
- The condition may be associated with hyper acidic gastric secretion.



Atrophic Gastritis III- 4.-3.322

Stomach				
	Wall:	Thin specially at fundus Fibrosed		
	Mucosa:	Thin (so that submucosal vessels shine through it) Smooth Lack of rugae (flattened)		
	Contents:	Excess of mucus		

With atrophic gastritis there may be nausea, vomiting and indigestion as well as:

N.B.:

1. *Hypochlorhydria.*
2. *Achlorhydria.*
3. *Achylia.*
4. *Marked anaemia (absence of the intrinsic factor).*
5. *Doubtful inter-relation to cancer of stomach.*



Figure 122
Nature Chronic Gastritis
Specimen No. III-3.321
Reference P. 229



Figure 123
Nature Gastritis (atrophic)
Specimen No. III-3.322
Reference P. 229

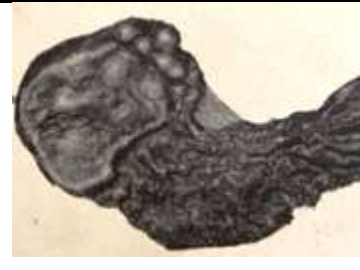

Figure 124
Nature Mucoid Carcinoma (stomach)
Specimen No. III-3.556
Reference P. 229

