

**XVII. Diseases of the Digestive System**

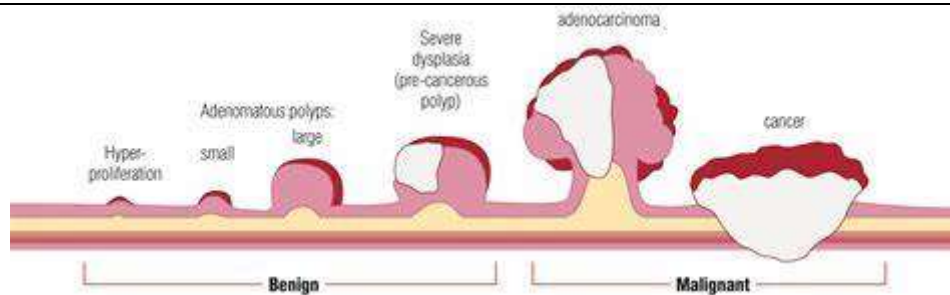
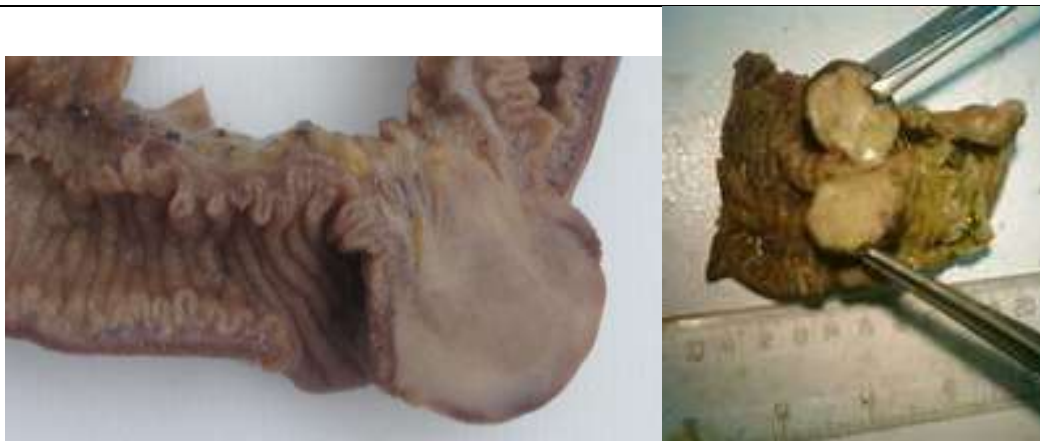**Myoma**

*A piece of small intestine:*

Shows a benign tumour

*The tumour:*

- Arising from the wall
- Protruding into the lumen of intestine
- Moderately-large
- Has a short pedicle
- Fleshy in consistence and appearance
- No evidence of:
  - Invasion or destruction
  - Necrosis or haemorrhage



***N.B.:***

- *Histologically, it proved to be a myomatous neoplastic tissue.*
- *In general, benign tumours of the small intestine are rare or uncommon.*

***They include:***

1. *Myoma;*
2. *Fibromyoma.*
3. *Fibroma;*
4. *Neurofibroma.*
5. *Haemangioma;*
6. *Lymphangioma.*
7. *Lipoma.*