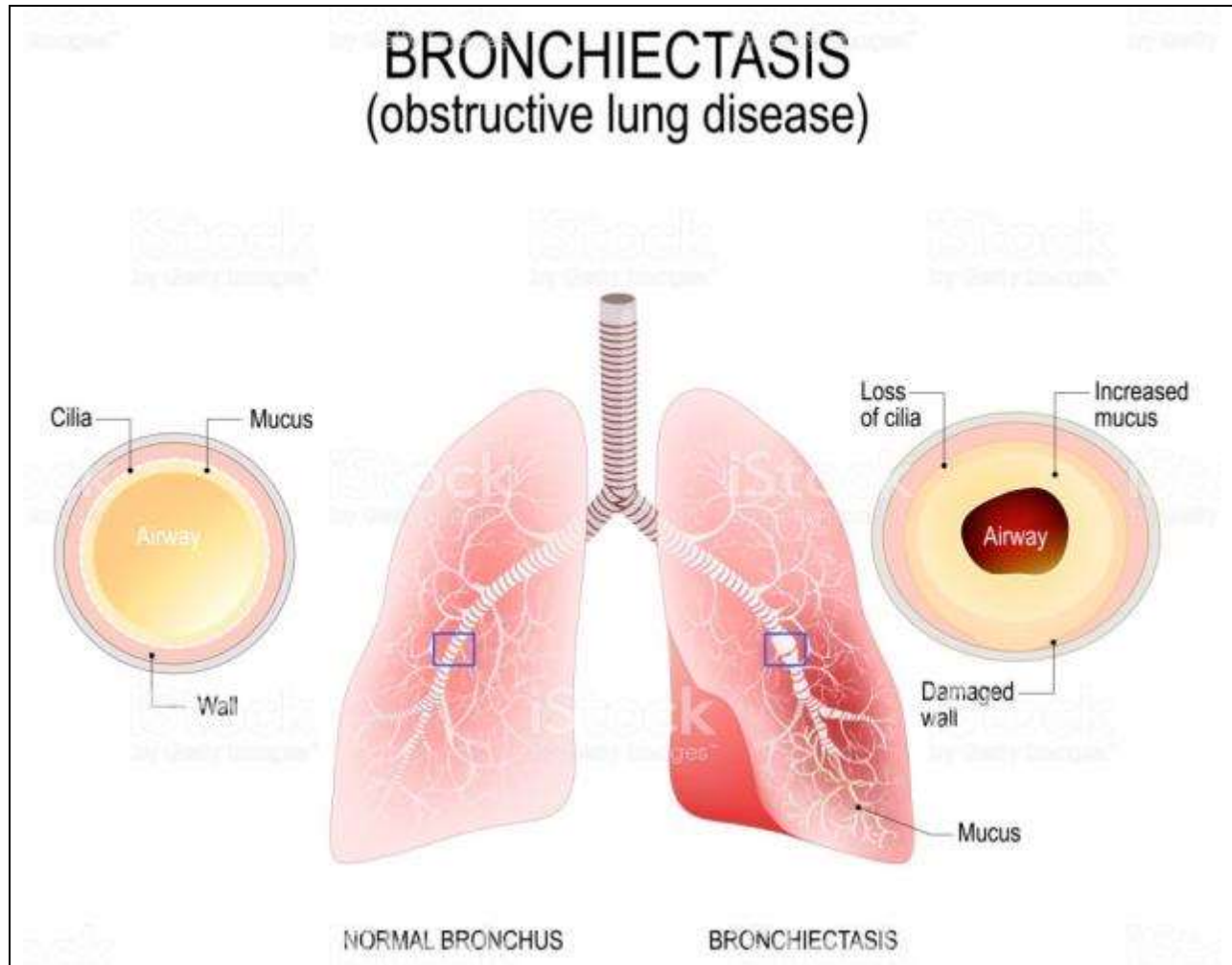
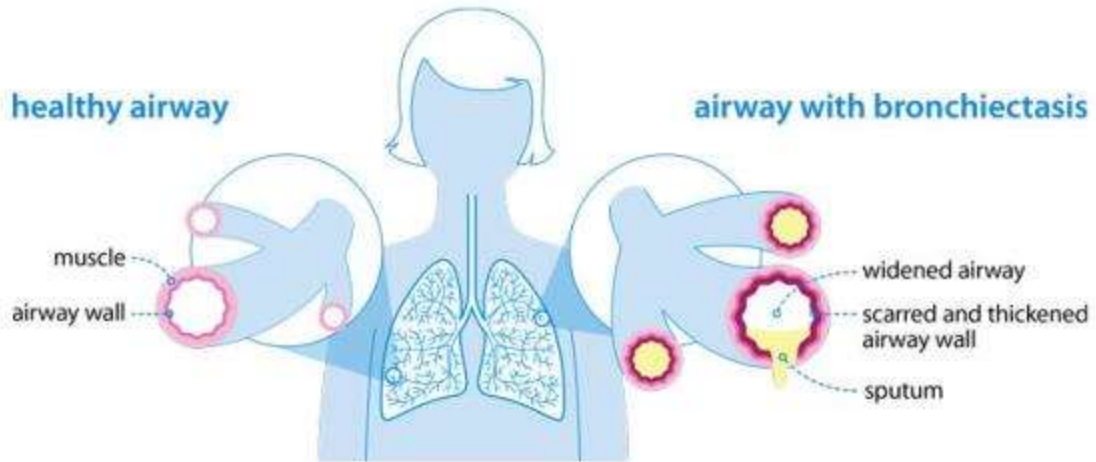


XVI. Diseases of the Respiratory System
167



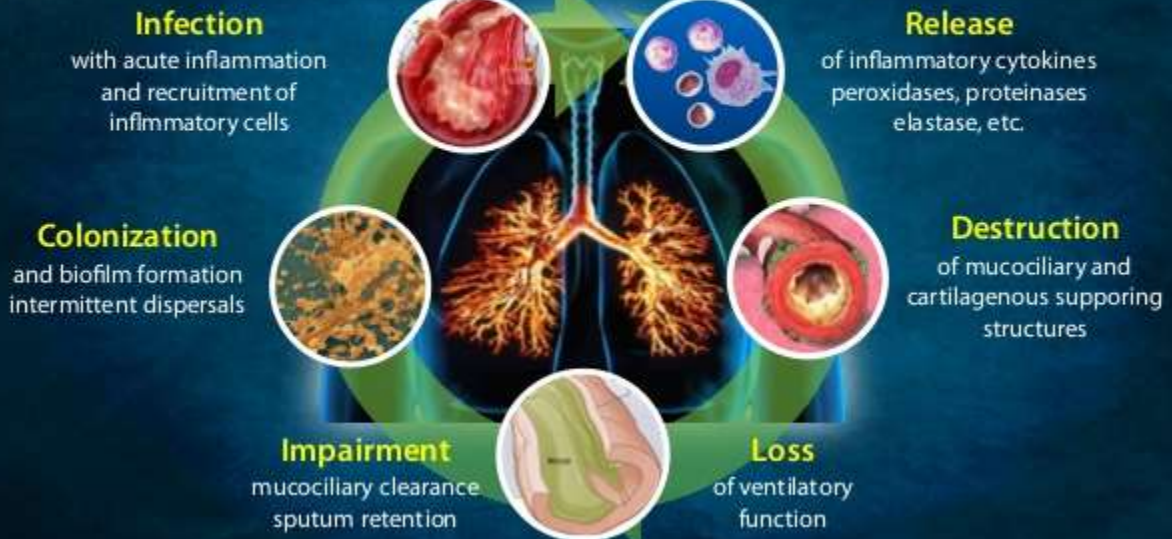Bronchiectasis		II-5.032		
Lung	<ul style="list-style-type: none"> • Large in size (voluminous) • Irregular external surface 			
	Cut surface:	<ul style="list-style-type: none"> • Shows multiple <u>cystic cavities</u> • Dilated bronchi • Excess fibrosis • Emphysematous areas 		
Cystic cavities	<ul style="list-style-type: none"> • Numerous • More at lowermost parts (more diffuse at lower lobe). • Well-defined • Variable in size (1–5 cm, in diameter) • Rounded (usually) • Appear fusiform (and/or cylindrical) • Few are saccular or irregular 			



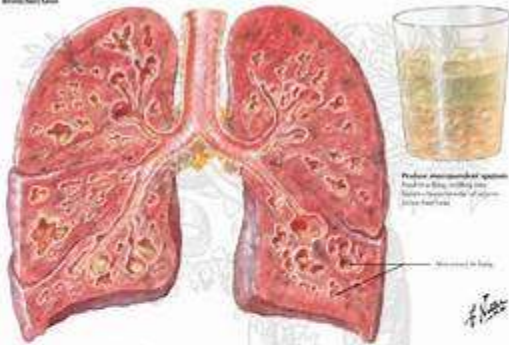
	Lining:	<ul style="list-style-type: none"> • Thin (most cavities) • Thick-walled (few) • Smooth • Swollen and shaggy (some) • Congested • Ulcerated (slightly) 	
	Contents:	<ul style="list-style-type: none"> • Viscid secretion • Mucopurulent exudate • Yellowish-red • Blood-stained 	
	Walls:	<ul style="list-style-type: none"> • Thickened (few) • Fibrous • Surrounded by excess fibrous tissue 	
Bronchi:		<ul style="list-style-type: none"> • Dilated • Congested • Filled with exudate • Show excess peribronchial fibrosis • Some are thickened (by fibrosis) 	
Interlobular septa:		<ul style="list-style-type: none"> • Show excess of fibrous tissue • Pale white • Thickened 	
Pleura:		<ul style="list-style-type: none"> • Dull • Thickened • Fibrosed • Pale greyish-white 	



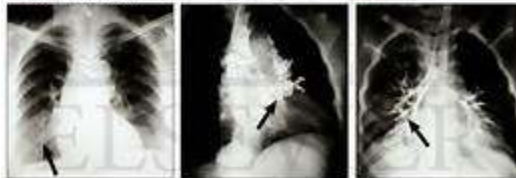Pathogenesis of Bronchiectasis: The Vicious Cycle



Bronchiectasis

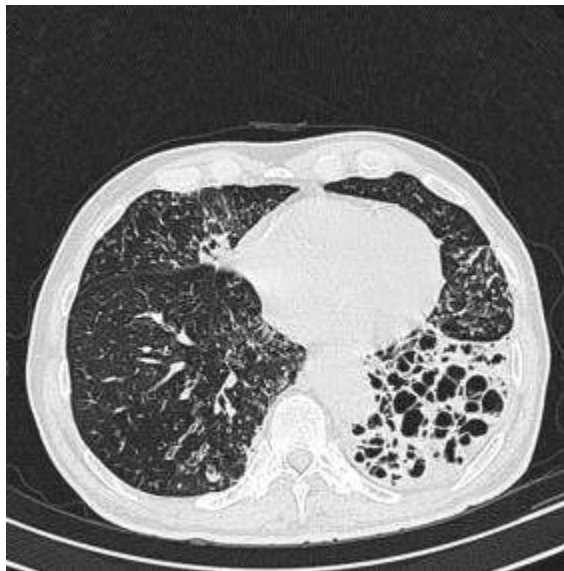

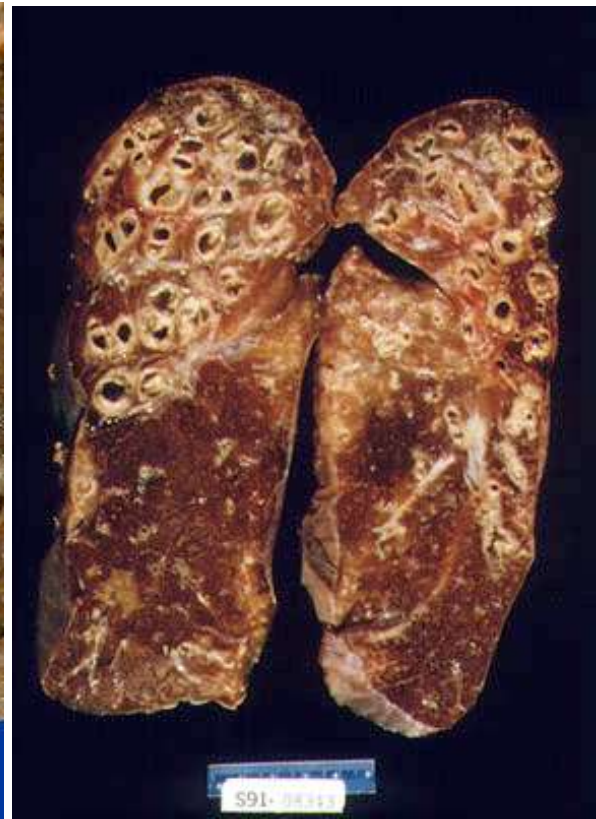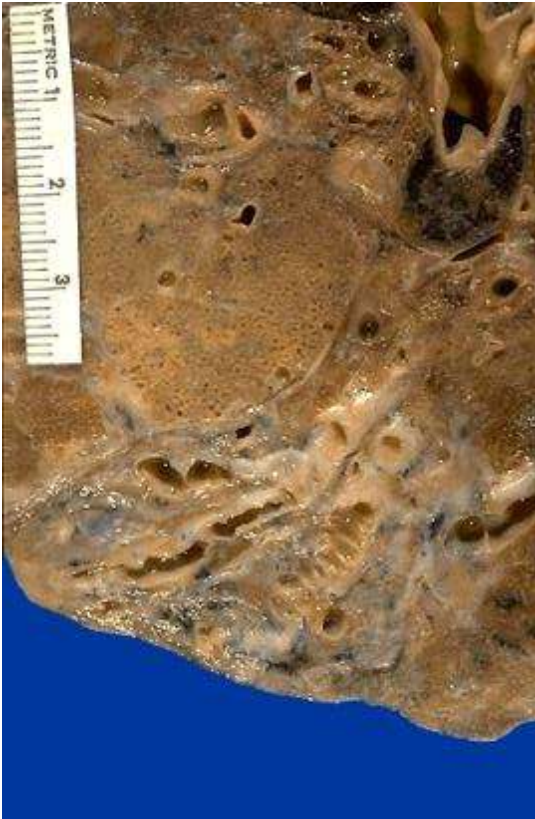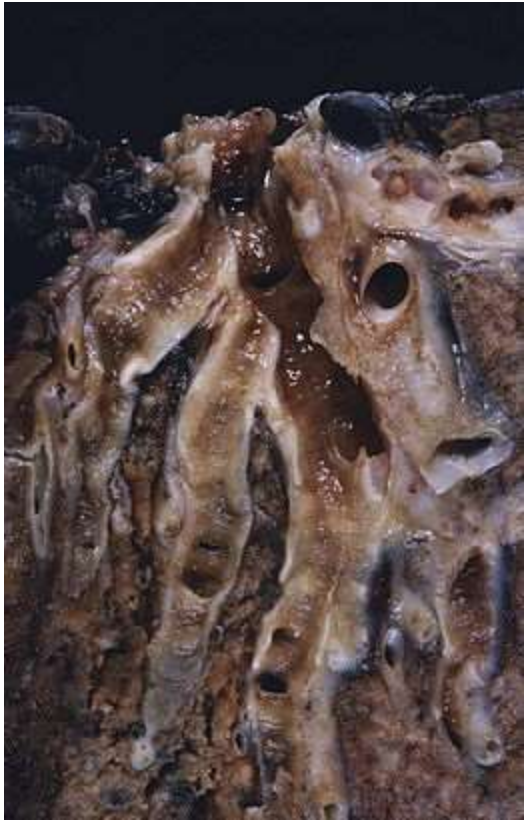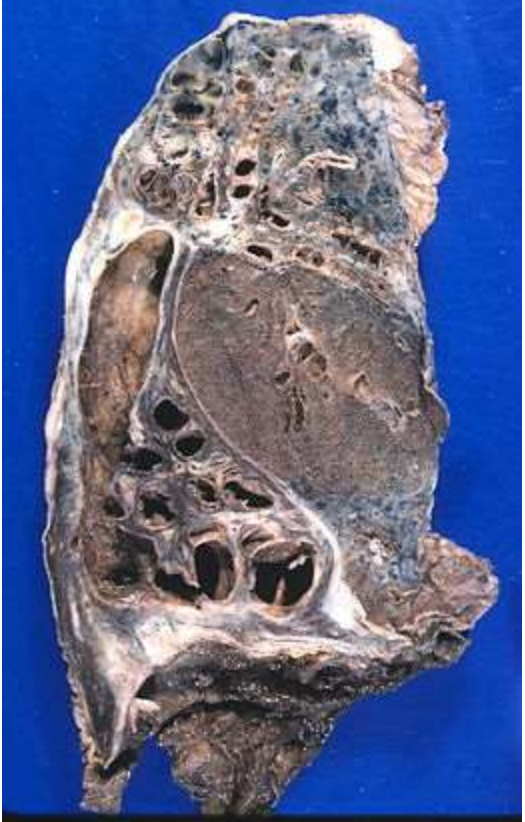Medical illustration of bronchiectasis

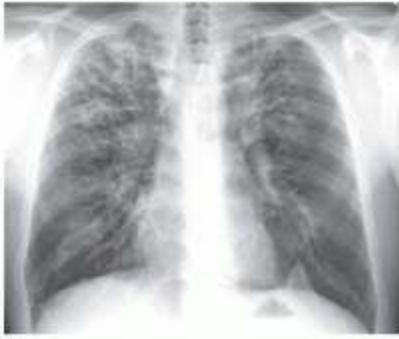

© Elsevier, Inc. and Netter Images, Inc. All rights reserved. Netter Images, Inc. and Netter Images, Inc. All rights reserved.

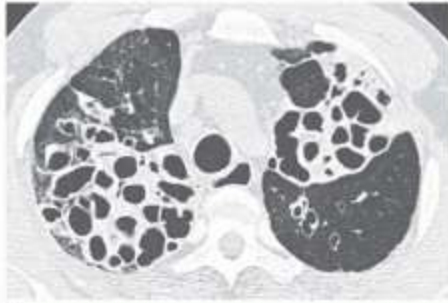
© ELSEVIER, INC. - NETTERIMAGES.COM



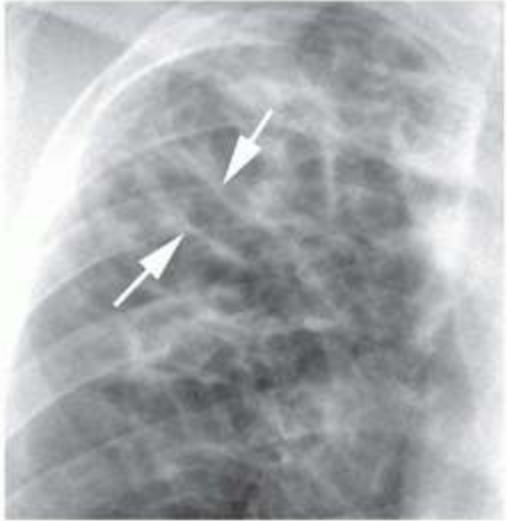




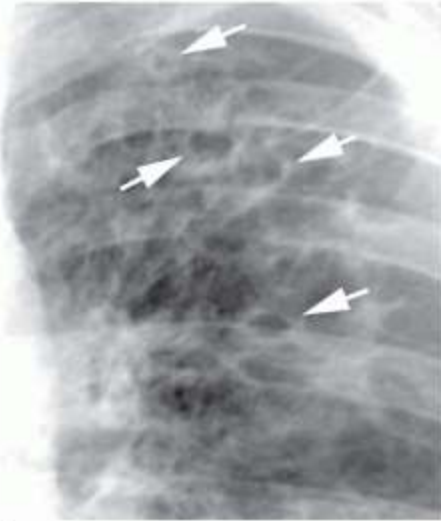A



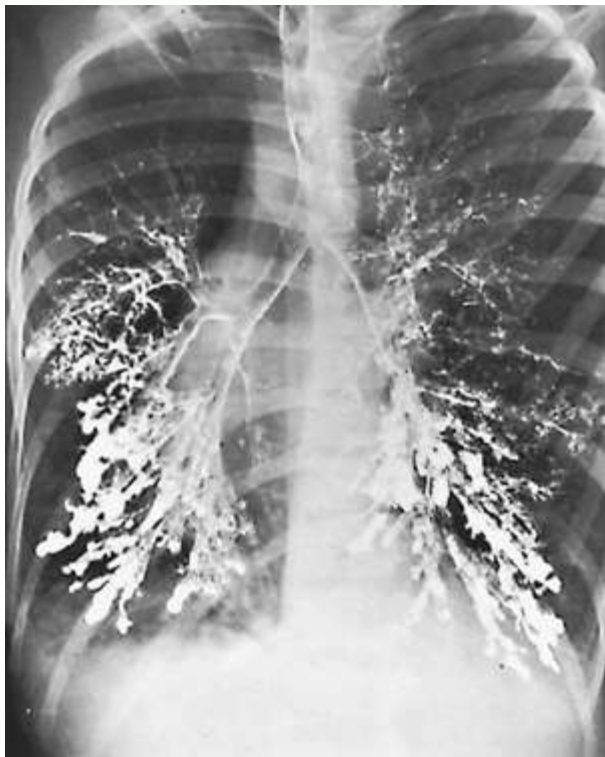C



B



D

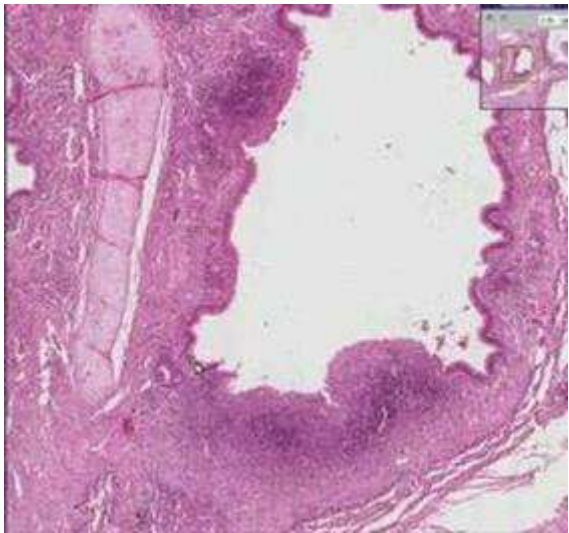

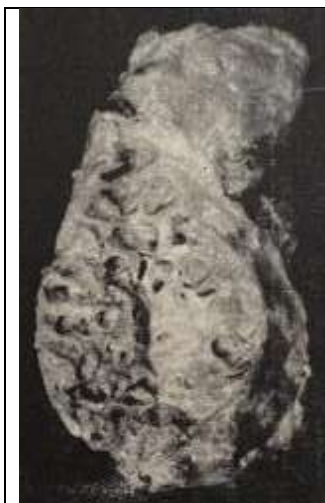


Figure 75 a
Nature Bronchiectasis
Specimen No. II-5.032
Reference P. 167



Figure 75 b
Nature Bronchiectasis
Specimen No. II-5.032
Reference P. 169