

XVIII. . Diseases of Liver, G. Bladder, Pancreas & Peritoneum Liver

Ascariasis of Liver III- 6. 413

Liver:	<ul style="list-style-type: none"> Shows Ascaris worms
Ascaris worms:	<ul style="list-style-type: none"> Numerous Protruding from the bile ducts

N.B.:

- This is an ectopic site (abnormal).
- Most probably, the entry of the worms was through the ampulla of Vater in the duodenum.
- This patient had suffered from obstructive jaundice.
- Numerous Ascaris worms were found in his intestines.

The wandering of adult worms may be into:

- (1) Bile ducts → jaundice.
- (2) Vermiform appendix and stomach → vomiting,
- (3) Small intestine → obstruction and perforation → peritonitis and
- (4) Pancreatic duct → pancreatitis.

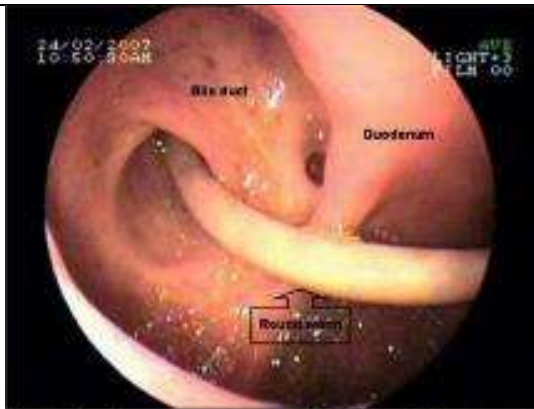


Figure 3: An ascaris present across the choledochoduodenostomy stoma

