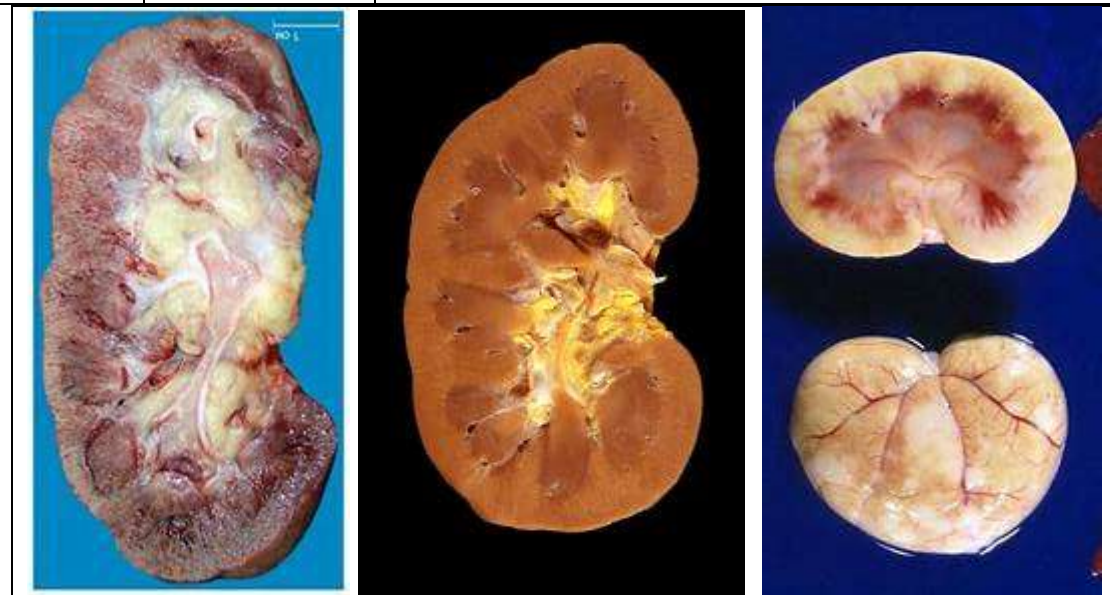

## XIX. Diseases of the Urinary System

Fatty Change Kidney (degeneration)		
<b>Kidney</b>	<b>Size:</b>	<ul style="list-style-type: none"> <li>• Slightly enlarged</li> </ul>
	<b>Capsule:</b>	<ul style="list-style-type: none"> <li>• Strips off easily</li> </ul>
	<b>Subcapsular surface:</b>	<ul style="list-style-type: none"> <li>• Smooth</li> </ul>
	<b>Consistence:</b>	<ul style="list-style-type: none"> <li>• Slightly soft</li> </ul>
	<b>Cut surface:</b>	<ul style="list-style-type: none"> <li>• Pale</li> </ul>
	<b>Cortex:</b>	<ul style="list-style-type: none"> <li>• Pale (in general) and thick</li> <li>• Yellow spots and streaks</li> </ul>
	<b>Medulla:</b>	<ul style="list-style-type: none"> <li>• Still differentiated from cortex</li> </ul>



### **N.B.:**

#### ***Fatty degeneration in the kidney***

##### **Patchy:**

As in

- **Bright's disease** and in
- **Chemical intoxications.**


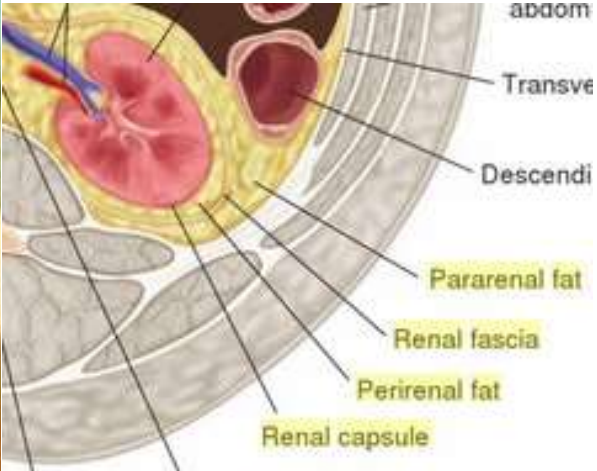
(The kidney shows a mottled or speckled appearance of the cortex).

##### **Diffuse:**

As in

- Severe anaemia,
- Diabetes mellitus,
- Bacterial toxins and
- Chemical poisons

(The kidney may be enlarged, pale and yellow; and, the condition may be so severe as to lead to renal failure).

<b>Fatty Infiltration</b>		<b>IV- 1.122</b>
<b>Kidney:</b>	<b>Size:</b>	<ul style="list-style-type: none"> <li>• <i>Small</i></li> <li>• <i>Atrophied (pressure atrophy)</i></li> <li>• <i>Is surrounded by excessive fatty tissue</i></li> </ul>
	<b>Renal pelvis:</b>	<ul style="list-style-type: none"> <li>• <i>Surrounded by marked amounts of yellow fat</i></li> </ul>
<p><b>N.B.:</b>  <i>The fat appears in excess :</i></p> <ol style="list-style-type: none"> <li>1. <i>In the capsule (peri-nephric).</i></li> <li>2. <i>Around the pelvis (peri-pelvic).</i></li> </ol>		
<div style="display: flex; justify-content: space-around;">   </div>		
<p><b><i>Causes of fatty infiltration</i></b></p> <ol style="list-style-type: none"> <li>1. <b>Metabolic derangement.</b></li> <li>2. <b>Lack of lipotropic factors.</b></li> <li>3. <b>Chronic alcoholism.</b></li> <li>4. <b>Dietary deficiency and hormonal disturbances.</b></li> </ol>		