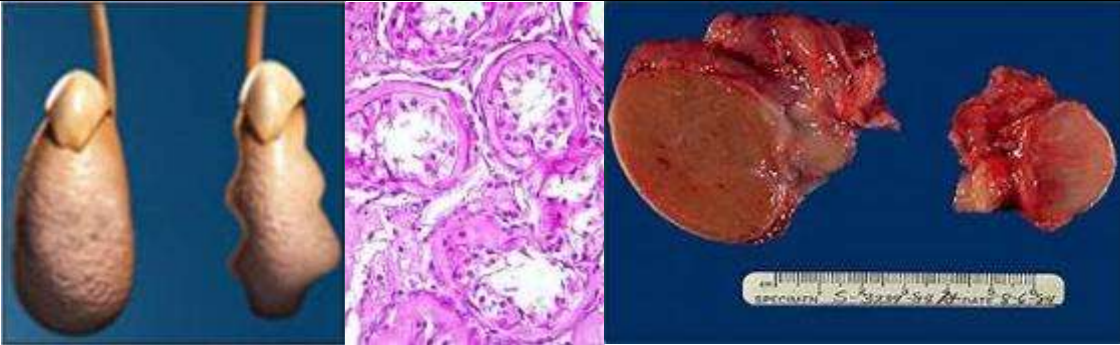


XX. Diseases of the Male Genital System

Testicular Atrophy IV-9-17

Testicle:	Size:	Is small			
	Shape:	Ovoid			
	Cut surface:	Dense white Fibrosed			
	Consistence:	Firm			



Testicular atrophy

- Atherosclerosis
- Inflammatory lesions (Orchitis)
- Cryptorchidism
- Hypopituitarism
- Malnutrition
- Irradiation
- Excessive Estrogens:
 - Antiandrogens in Tx of prostatic cancer
 - Cirrhosis of liver

N.B.1:

Causes of atrophy of testes

1. Senility.
2. Arteriosclerosis.
3. Post-inflammatory changes.
4. Hormonal disturbances.
5. Hypopituitarism.
6. Excessive Oestrogen.
7. Irradiation.
8. Deficiency in food and vitamins.
9. Undescended or mal-descended states.
10. Congenital reduction in size.
11. Improper development (**Klinefelter's syndrome** with eunuchoidism, gynaecomastia, high urinary excretion of gonadotropins, small testes and deranged testicular formations (azoospermia and male subfertility)).

