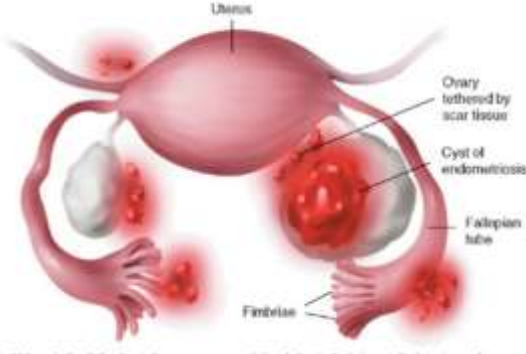


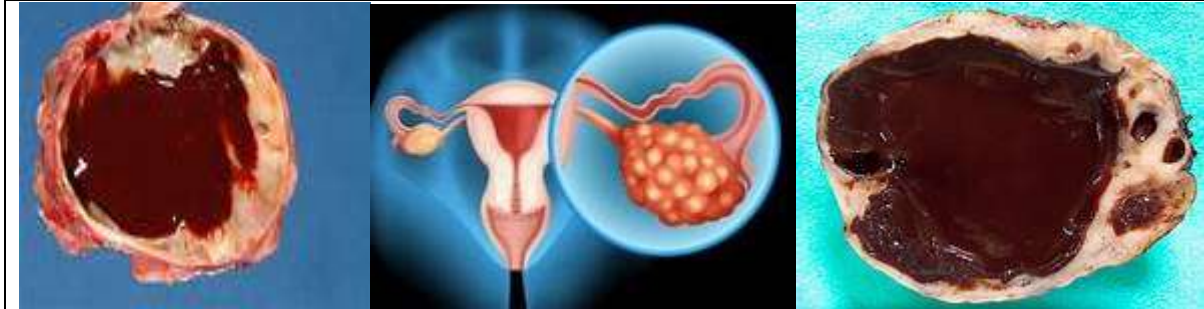
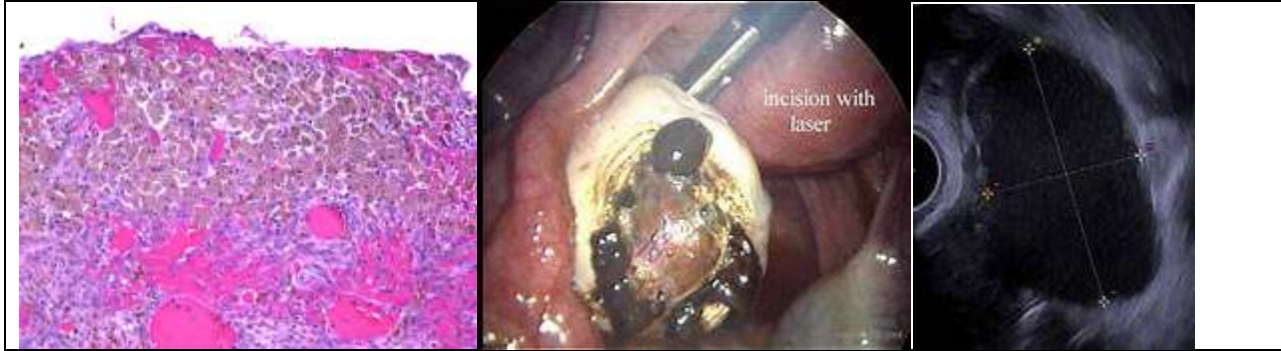


XXI. Diseases of the Female Genital System

Endometrioma (endometriosis)					
Ovaries:	<ul style="list-style-type: none"> • Slightly enlarged • Show Implants 				
	<table border="1" style="width: 100%;"> <tr> <td style="vertical-align: top;">Implants:</td> <td> <ul style="list-style-type: none"> • Cysts • Nodules • Small in size (0.5—5 mm.) • Projecting over the surface • Dark red in colour • Slightly bluish tinge </td> </tr> <tr> <td style="vertical-align: top;">Cysts:</td> <td> <ul style="list-style-type: none"> • Numerous • Very small (minute) • Some are relatively-large (0.5–5 cm.) • Rounded (majority) • Few are ovoid • Thick-walled • Yellowish-white (in general) • Few are brownish (chocolate-coloured cysts) • Contain viscid dark brown altered menstrual blood </td> </tr> </table>	Implants:	<ul style="list-style-type: none"> • Cysts • Nodules • Small in size (0.5—5 mm.) • Projecting over the surface • Dark red in colour • Slightly bluish tinge 	Cysts:	<ul style="list-style-type: none"> • Numerous • Very small (minute) • Some are relatively-large (0.5–5 cm.) • Rounded (majority) • Few are ovoid • Thick-walled • Yellowish-white (in general) • Few are brownish (chocolate-coloured cysts) • Contain viscid dark brown altered menstrual blood
Implants:	<ul style="list-style-type: none"> • Cysts • Nodules • Small in size (0.5—5 mm.) • Projecting over the surface • Dark red in colour • Slightly bluish tinge 				
Cysts:	<ul style="list-style-type: none"> • Numerous • Very small (minute) • Some are relatively-large (0.5–5 cm.) • Rounded (majority) • Few are ovoid • Thick-walled • Yellowish-white (in general) • Few are brownish (chocolate-coloured cysts) • Contain viscid dark brown altered menstrual blood 				
  					
<p>N.B.: Histologically, the cyst-wall showed endometrial glands. Chocolate-coloured cysts appear close to the surface of the ovary and if any of these haemorrhagic cysts get ruptured, it may be followed by implants on the peritoneum.</p>					



Case 58: Endometriosis of the ovary

