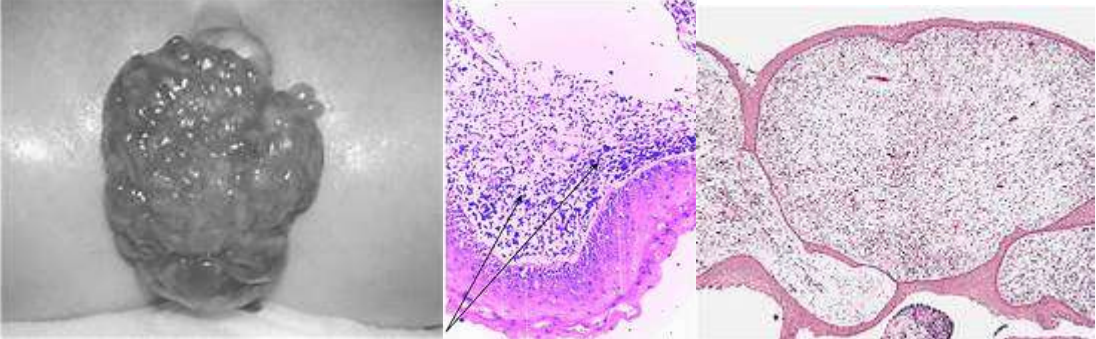


XXI. Diseases of the Female Genital System

Sarcoma Botryoides	
Vagina:	<ul style="list-style-type: none"> Shows a tumour
The tumour:	<ul style="list-style-type: none"> Is filling, and has protruded from, the vagina Large in size (bulky). Polypoid and bulbous in form and rounded in shape With grape-like fronds Areas appear haemorrhagic and others are solid Is greyish-yellow in colour Soft-gelatinous (and friable) in consistence
	
<p>N.B.1:</p> <ul style="list-style-type: none"> Sarcoma Botryoides (carcino-sarcoma) is a rare tumour which occurs at young ages and is derived from the primitive multipotential mesodermal cell. It arises in the vagina, cervix or the fundus of the uterus → bloody-discharge + pain. In children → local invasion → obstruction to urinary passages or/and penetration in the peritoneal cavity. In adults → rapid growth + metastases to regional lymph nodes and distant organs 	
